



PATIENT PRESENTING CLINICAL SIGNS

Remy Migneault large SQ mass on right ventral chest, CT scan to determine extensiveness of chest. Mass fist noted about 8 months ago as size of golf ball, has steadily grown since then. Now much larger, feels firmly attached. Previous cytology with rDVM suggestive of lipoma

SPECIES

Canine

Abnormal PE/Chem/CBC/UA Results: None

COMPUTED TOMOGRAPHIC STUDY OF THE THORAX

BREED

Plain and post contrast studies are available for review.

Labrador Retriever
Mix

COMPUTED TOMOGRAPHIC FINDINGS

SEX

MN

The CT study reveals a large well circumscribed ovoid subcutaneous uniformly fat attenuating mass along the right ventral thoracic wall measuring ~ 10 by 7 by 6 cm. The mass is entirely extra thoracic located within the subcutaneous tissue. It is positioned adjacent to right ribs 4-10 without evidence of invasion. Uniformly fat attenuating internal structure with mild internal septation is seen. The margins are smooth with preserved surrounding fascial planes. No evidence of muscular invasion, rib lysis, periosteal reaction or extension into the intercostal spaces is seen.

AGE

9

The lungs are normally aerated with no evidence of pulmonary nodules or masses.

The mediastinum is unremarkable.

INTERPRETED BY

Nele Eley (Ondreka),
DVM Dr. med. vet.,
DipECVDI

The heart presents within normal limits for size and morphology.

No pleural effusion or pleural thickening is seen.

The trachea and main stem bronchi are within normal limits.

COMPUTED TOMOGRAPHIC DIAGNOSIS

HOSPITAL NAME

Westford Veterinary
Emergency and
Referral Center

- Large well-defined subcutaneous fatty mass on the right ventral thoracic wall consistent with benign lipomatous tumor.
- No CT evidence of local invasion or metastatic disease

REFERRING VET

Mallory Watson

INTERPRETATION OF FINDINGS & FURTHER RECOMMENDATIONS

The imaging characteristics strongly support a benign lipoma. Uniform fat attenuation, well-defined capsule, lack of contrast enhancement and lack of invasion of adjacent anatomic structures are typical for benign lipoma. There are no features suggestive of infiltrative lipoma or liposarcoma in this study. Importantly, the mass remains surgically separable from the thoracic wall and does not involve critical structures.

INVOICE

23915

DATE

02/18/2026



PATIENT

Remy Migneault

SPECIES

Canine

BREED

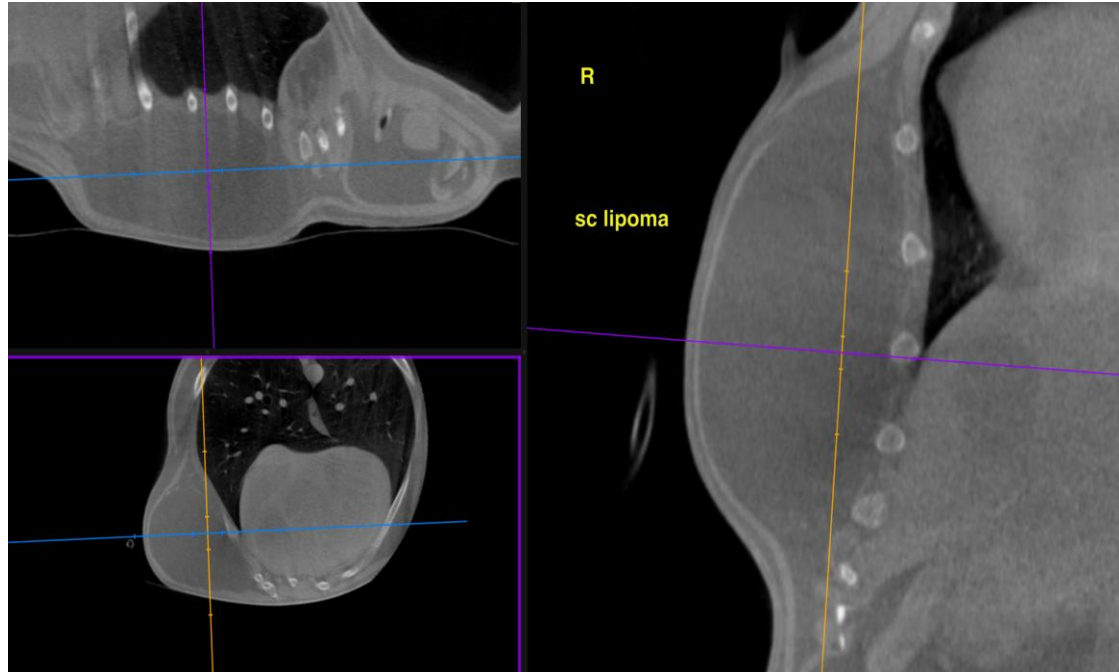
Labrador Retriever
Mix

SEX

MN

AGE

9



The information and recommendations provided are based on the images presented by the referring veterinarian. No evaluation can be communicated regarding pathology that was not visible in the image/video clips provided.

INTERPRETED BY

Nele Eley (Ondreka),
DVM Dr. med. vet.,
DipECVDI

Thank you for this referral. If the clinical or image interpretation does not parallel your findings or if I can be of any further assistance please contact me.

HOSPITAL NAME

Westford Veterinary
Emergency and
Referral Center

Nele Eley (Ondreka), DVM, Dr. med. vet., DipECVDI
European Specialist in Veterinary Diagnostic Imaging, Cert. Radiology,
Senior lecturer University of Giessen/Germany, Veterinary Faculty, Department of Radiology.
info@sonopath.com

REFERRING VET

Mallory Watson

INVOICE

23915

DATE

02/18/2026